

Contemporary Evaluation of Thermal Breast Screening

Anthony Piana, DC

Alexander Sepper, MD, PhD

Background

Breast cancer is one of the major problems of modern oncology, and has certainly received the most attention. The World Health Organization (WHO) estimates that by 2030 there will be 26.4 million new cases of breast cancer annually worldwide, and 17 million people will die from this terrible disease.

Breast cancer is frequently found in women predominantly between the ages of 32-38 years old who are pregnant or have just given birth. According to statistics, breast cancer occurs 1 in 3000 pregnancy cases. About 3% of all cases are diagnosed during pregnancy, and 25% are seen in women less than 45 years of age. It is these women who currently do not have a method of annual screening, and in turn leave behind young families when they die. Adding a valid method of screening for these mothers will allow for a greater survival rate as well as a decrease in overall healthcare expenses. Early detection of breast cancer implies earlier treatment, therefore saving more lives, which the current system of conventional screening mammography has not achieved.

Earlier diagnosis will aid in decreasing the cost of overall healthcare in several areas. First, the number of full radical mastectomies will be reduced and more lumpectomies will be performed. This will cut down on the cost of not only the hospitalization stay, but the time of disability. There would be less reconstructive procedures required as breast integrity can be maintained. Finally, the need for costly chemotherapy could be lessened in the absence of lymph node involvement.

The FDA officially cleared thermography in 1982 as an adjunctive method for the diagnosis of breast cancer. Thermography is a complementary method of the screening process for breast cancer with no contact and allows for multiple screenings of women at any age, including pregnant women. The level of development of thermographic engineering is currently very high. This level in technology allows for mobility to serve remote locations with the added benefit of less cost. The information displayed in the images and user-friendly systems are far superior to previous medical thermographic equipment. The *No Touch Breast System* developers of the thermographic technology have recently been recognized for their work by the Government with a \$900,000 grant to continue development.

This discussion establishes that thermography has its own niche in the methods of diagnosing breast cancer when used as an adjunct to mammography, and can improve the efficacy of such a diagnosis.

Brief History of Medical Thermography

The science of medical thermology was first published in 1956 with an analysis of 26 breast cancer cases by Dr. Robert Lawson (1). Over 800 peer-reviewed articles have been published since that time including several contemporary pieces. While the nature of science is to build on past research, the challenge is that older information was dependent upon analog equipment, and not the improved technology utilized today. Modern digital equipment is noted to be far more sensitive than equipment employed when older studies were performed.

Many of the current methods of interpretation are utilizing a historical system of TH risk factor ratings. This originated from studies performed in the late 1970's with the use of analog equipment on statistically small groups of patients. The patients were monitored over time and their rate of breast cancer development was studied with assigned corresponding risk factors. Several problems existed within this study including the fact that 10% of TH1 cases (lowest risk factor) went on to develop clinically confirmed breast cancer in mammograms with subsequent biopsies.

The use of the term "risk factor" in Thermology is invalid. The thermal patterns seen are not "risk factors", but actually early signs of cancer due to inflammation, neoangiogenesis, or estrogen related activity. A mammogram detects tumors dense enough to be visualized on radiographs. Physiologically, before a dense mass appears, heat is generated in and around the cells where the cancer is developing, which is rendered on thermal images. A potential use for "risk factor" prediction may lie in the thermal identification of estrogen dominance.

Using mammogram technology to initially screen for cancer rather than thermal imaging is like waiting for a tire to blow out instead of inspecting its' treads. Thermography sees the metabolic indicators of cancer earlier, therefore being a great adjunct to anatomical screening.

Risk factor assessment should be abolished. The use of thermal imaging for breast cancer screening should be utilized for initial analysis and establishing baselines for each patient. Changes in thermal activity must then be investigated and assigned appropriate clinical investigation including an ultrasound and diagnostic mammogram.

Current Screening Methods of Breast Cancer

The US National Cancer Institute recommends mammography screening for breast cancer only in women older than 40-50 years because the mammary glands of young nulliparous women have a high density. Tumors are not easily distinguished from the dense breast tissue resulting in many false negatives. Furthermore, the NCI states that X-ray radiation itself is a risk factor for the development of malignant tumors. Frequent radiation is not advised by any medical institution. Gotzsche and Olsen (2) studied a meta-analysis of more than 500,000 screening mammographic images that showed mammography causes more cancer cases than it prevents. Statistics show that for every 1,000 mammography examinations performed only one death was prevented, but six were caused.

A screening study in the former Soviet Union (USSR) of 18,000 women diagnosed 3.5 breast cancers per thousand (3). This study used a Barnes Thermovisual device where only a few staff members screened

all women in one week. This rate of detection is comparable to screening with mammograms, but with less expense and more efficient testing.

Metabolism of Tumors and Tumor Growth

It is well understood that cancer cells, through the release of Vascular Endothelial Growth Factor (VEGF), develop a blood supply through a process called angiogenesis. Growing cells and increased blood supply produce measurable amounts of heat that can be detected by thermometric devices. The scientific community employs the uses of infrared thermal imaging to accurately measure heat both quantitatively and qualitatively, which are useful in evaluating skin temperatures of the human body; and therefore the skin overlying breast cancer.

Tumor growth varied considerably between subjects, with 5% of tumors taking less than 1.2 months to grow from 10 mm to 20 mm in diameter, and another 5% taking more than 6.3 years. The mean time a tumor needed to grow from 10 mm to 20 mm in diameter was estimated as 1.7 years, increasing with age.

Hobbins (4) at the University of Wisconsin showed that 70% of tumors are found up to 10 years prior to identification on a mammogram with thermal imaging. This study was paralleled in a study performed in the USSR showing the ability to detect tumor development in the preclinical phase.

Temperature Measurements

With the use of scientifically calibrated thermal imaging equipment, a quantitative measurement is possible. These same infrared cameras are utilized throughout the scientific community and have been established as reliable devices of accurate measurement. It is important to maintain room temperature at a consistent level. Patients' metabolic rate on the particular day of study may fluctuate. Emissivity, an object's ability to radiate infrared radiation is a consideration. Lotions, deodorant, and other factors can change the infrared readings due to emissivity differences. Qualitative measurement provides a relative temperature difference and is an extremely effective way to analyze vascular patterns independent of identical temperature and emissivity. Delta T measurements are used by the thermographer to analyze relative differences in body heat. This is done using symmetrical points for quantitative measures independent of the patient's base thermal state. Established protocols must be followed in order to receive reliable data.

Automated Interpretation

Some researchers (5, 6) have attempted to use automated interpretation software for breast screening. The drawback is that computerized programs have not been successful in the evaluation of vascular heat impressions used to locate probable pathologies through inverse grayscale imaging. Automated software is limited to delta T measurements. These studies show a comparison between the percent of success at finding malignancies compared to that of mammogram technology and not from a screening standpoint. The 97% sensitivity in a Cornell study concluded that 58 of 60 tumors were identified from a suspect mammogram and were confirmed after further biopsy. This is not saying it found 58 of 60

tumors in a screening population, but 97% of what mammography screening found. While these numbers are impressive, thermography offers further potential as an initial screening, independent of mammographic screening.

Anatomy versus Physiology

No current screening test can diagnose breast cancer. Current anatomical tests include: ultrasound, mammography, and MRI. Thermography is a physiologic heat detection exam. Anatomical tests identify structures, which cannot lead to a complete understanding of the pathological process. Thermography, as a study of physiology, does not assess anatomy or structure, but senses the thermal radiation from the surface of the body (breast), revealing the metabolic activity of the area studied.

Thermography is a method of objectification of physiology with its inherent advantages and benefits. It does not replace the x-ray and ultrasound, but allows clarification of physiological processes.

Thermography benefits include: the early detection of disease in cases that are too small to be visualized on anatomical testing; following the effectiveness of therapeutic interventions (where is the benefit in this statement?); aid in decision making for the need for surgery, or what type of surgery to perform. Anatomical tests are unable to find: densities of tumors 1-5mm and smaller; metabolic activity of the cancer cells; the change in activity of the disease process in response to treatment. Thermal imaging fills these needs.

New Model of Thermographic Analysis

Current methods of assessment used to interpret thermal images for risk analysis do not reference any contemporary studies, but rather are based on prior research using analog equipment. The authors believe that the categorization of breast cancer risks is a strength of breast thermal imaging. The strength of modern thermology lies in the ability to evaluate vascular heat patterns and their deviation from baseline studies. The risk factors previously used are taken into consideration, not as risk factors, but as abnormal physiology of the breast. The thermologist acts more as a radiologist in identifying abnormal versus normal; yet the former focuses on physiology while the latter analyzes anatomy. Baseline studies are important for periodic comparison.

Normal Thermal Breast Physiology

It is important for the thermologist to become familiar with normal breast patterns. Normal breast physiology will vary in women at different phases of life. Hormonal mottling patterns will be seen in pre-menopausal women after puberty. Normal physiology will show fairly symmetrical vascular bundles. Post-menopausal women will show signs of hormone expression diminishing with the aging process.

Abnormal Thermal Breast Physiology

Inflammatory conditions in the breast are represented by darker patterns in the inverse grayscale and usually white or red in color palette. This is dependent upon the scaling and range used by the individual

thermographer. These may represent different forms of pathology, which includes breast cancer, mastitis, injury, and any other condition that would raise the temperature of the breast locally. In traditional analysis, the threshold for two bilateral points was 2.0 degrees Celsius. The studies were designed in a pre-mammographic era where DCIS was not as prevalent. We have found when less metabolically active tumors, such as DCIS, show on thermographic images, that the delta T is typically lower than 2 degrees. Another challenge, is that measurements over two degrees are commonly seen with fibrocystic breasts. Using this threshold value poses a problem of missing many cancers, as well as creating a substantial degree of over diagnosis with fibrocystic breast syndrome.

Frequently, we find areas of hypothermia in the breast unilaterally. These cold areas may represent lipomas or a sympathetic nervous system response. Nerve related findings might be the result of a spinal lesion, local CRPS, or trauma to the breast. Several cases are noted where biopsy trauma created hypothermic temperatures that masked underlying heat. Cold areas also affect the different temperature readings creating a much higher delta T on the opposite side, which may lead to false suspicion. We also identified viscera-somatic reflexes from contralateral pathologies that create a cold area. It is also possible to have similar reflexes from another more remote origin.

Bilateral nipple differences in early studies claim that a difference of 1.0 degree Celsius is considered a risk factor. We believe that any significant difference in nipple temperature is cause for suspicion. Heat from deep within the breast is conducted to the nipple. Some previous authors have separated the temperature difference between the areola and the nipple. The threshold of the areola has traditionally been 1.5 degrees Celsius. Until further mass studies are performed, these differences should be ignored and any heat difference in the areola and nipples should weigh heavily in the Thermologist's assessment. It is common to see hormone expression surrounding the nipple and areola. These findings are typically bilateral and are benign.

The axillary tail of the breast should be inspected very carefully for not only vascular patterns, but lymph node inflammation as well which may be metastatically related to a breast cancer, or an independent lymphoma. Small oval focal points of hyperthermia are pathognomonic for lymph node involvement. Lymph node heat may arise from metastatic origin or a primary tumor.

The axilla itself normally produces increased infrared readings compared to the neighboring breast tissue. This is partly due to its cavity radiator effect as well as being a warmer body area. It is important to note the relative and quantitative temperature differences. There is a significant difference in temperature with inflammatory breast cancer and other aggressive metastatic cancers.

Inflammatory breast cancer appears as global heat in the breast, but usually starts more locally in the upper outer quadrants. Significant differences in global heat warrant immediate further investigation, while early signs require a short-term follow-up. The traditional threshold of 1.5 degrees Celsius for global heat should be ignored, as this serious disease requires immediate attention at thresholds lower than 1.5C, especially with any symptoms of skin irritation. A case study has been provided for visual clarification (Fig. IBC).

The authors concur that there are an abundance of breast cancer cases discovered with thermal imaging that are not easily detected with mammographic studies. These include inflammatory breast cancers and tumors in body regions hard to visualize with mammographic screening. For example, tumors alongside the rib cage and near the sternum are not easily identified, as well as cancers in women with small or excessively large breasts.

Identifying Breast Tumors with Thermography

Neither thermography nor mammographic screenings are able to diagnose breast cancer. Tissue biopsy is the only method adequate to give a conclusive pathology report. One mechanism of improved accuracy was used in the USSR; it involved injecting a glucose solution into the patient, then waiting 60 minutes for a follow-up exam. This worked much in the same way as injecting radioactive glucose into a PET scan patient. Areas of increased metabolic activity were identified in the patients that were frequently referred for biopsy.

Fibrocystic Breasts

Thermal patterns indicative of fibrocystic breasts show extreme mottling patterns throughout the breast and into surrounding adipose. The delta T of these patients is typically in the 2.0C range, but not usually over 2.5C. Hormonal balancing and lifestyle changes should be implemented resulting in a reduction of the mottling as well as temperature, indicating successful treatment. This underutilized method may be an effective way to prevent cancer. Patients express interest in prevention over cure. More focus on research in this area is required.

Vascular Networks

Analyzing vascular networks is the most valuable aspect of thermal imaging in detecting breast cancer. Vascular images are like a fingerprint in that they are similar from test to test. Any change in this vascular network creates immediate suspicion upon follow-up baseline comparison. On initial testing, a trained thermologist would be highly accurate in the recognition of suspicious patterns through inverse grayscale imaging. Early thermographers created names for various vascular findings, these included: *Closed Vascular Anarchy, Star Vascular Anarchy, Moya-Moya Sign, Edge Sign, Bite Sign, Transverse Vascular Anarchy, Inferior Vascular Anarchy*, and several more. These were considered *risk factors* and were added to the TH rating.

The trained eye easily identifies abnormal or asymmetrical vascular patterns. These patterns may represent the individual's normal vascularity or neoangiogenesis of a pathological process. Older interpretation methods of vascular risk factors should be studied and used in context of identifying suspicious areas rather than risk assessment. Closed vascular patterns frequently identify underlying cancer with or without high delta T measurements. Serpentine, transverse vascular patterns and star vascular patterns also frequently locate malignancies. The *bulge sign* originates from underlying heat expanding the infrared image outline of the breast, and should be weighed heavily. Many vascular patterns are also the result of a patient's normal thermal imprint and show up more frequently with modern equipment than in previous years with less sensitive equipment. Some patterns may originate

from injuries to the breast. For example, a common benign finding is seen in the lateral breast from seat belt injuries in a car accident.

The authors believe that these patterns in many cases are considered to be suspicious, however more importantly an abnormal pattern is recognized. It is important to recognize normal versus abnormal patterns.

Calcification and DCIS

Thermography does not use radiation, nor does it test for density in any way, thus, does not detect calcifications present in the breast. Calcifications may be associated with ductal carcinoma in situ, and may be missed in some cases with thermal imaging if there is no associated inflammation or neoangiogenesis. The beneficial aspect to this is that there will be less over diagnosis as cited in the New England Journal of Medicine article of 2012, by Dr. H. Gilbert Welch of Dartmouth Medical School (7), regarding the failure of screening mammography. It is estimated that as many as 50 percent of breast cancer diagnoses are over-diagnosed. Thermography will commonly identify the more serious cases displaying higher vascularity.

Monitoring Temperature Changes

Increased delta T does not always accompany a growing tumor. In some cases, we have seen progressing tumors with lower delta T measurements on follow-up exam. The growth is not linear and may be a result of immune system function, hormone imbalance, or inflammation. The lack of Delta T increase does not guarantee lack of pathology. In case MK-1 (Fig. MK-1) it is apparent that tumor metabolism was not linear.

Metabolic Rate of Cancer

Thermography screening will be predominantly more aggressive with cancers that have higher metabolic rates, and therefore is a better screening test to assess which cancers may be life threatening. A developer of the *No Touch Breast System* commented that their system will be used primarily in India where they do not care about less aggressive forms of cancer like DCIS and will focus more on serious cases.

Metastasis of Breast Cancer

In addition to the diagnosis of breast cancer, thermography is very useful in the detection of regional metastases of cancer, particularly metastatic involvement of axillary and subclavicular lymph nodes. The main factor determining the prognosis of breast cancer is the presence of metastases in regional lymph nodes of the axillary and supraclavicular region. Five-year survival rates of patients without metastases is 82-90%, while with metastases is only 50-70% (8). Current diagnostic testing of these areas is challenging.

The most common method of locating metastases in the axillary lymph nodes and supraclavicular area are fine needle biopsies after palpating a lump. A negative biopsy does not guarantee the absence of metastasis since biopsies do not reveal more than 33% of metastases. (9) A Biopsy is an invasive method, which may increase the risk of dissemination of a tumor. As a result it is recommended that it not be over utilized. Thermography can lessen the use of this harmful and expensive procedure.

Using mammography for diagnosis of metastatic axillary lymph nodes is only 37% effective (5). This is due to poor radiological indicators in early forms of metastases, and the methodological difficulty of obtaining images in the upper part of the axilla. The value of ultrasound diagnosis in this area is slightly better, and excellent when combined with thermal imaging. The assessment of thermographic analysis of the axilla has a sensitivity of 95%, specificity 88%, positive predictive accuracy of 87.5% and a negative predictive accuracy of 95.6%. (10)

Supraclavicular images should look isothermal in lean patients and may show a small degree of hyperthermia in the medial clavicle due to the concavity of the surface being a cavity radiator. Angling the camera perpendicularly to this area will improve detection of pathology.

In metastatic lesions of the supraclavicular lymph nodes, the images appear hyperthermic and bilateral temperature gradients can reach 2°C or greater. These thermal signs can be detected at the earliest stages of metastasis development when it cannot yet be determined by other available diagnostic methods. A thermogram cannot accurately determine the location of the lesion in the lymph node to puncture, but when it detects such signs, the need for radiation therapy in the postoperative period is warranted.

Baseline Comparison

Many women have normal asymmetrical physiology of heat patterns in the breast. Each pattern again is like a fingerprint, and will be similar year after year. At times these patterns are acquired through traumatic origin and a new benign pattern will emerge; however, all new findings should be considered suspect until proven otherwise. It is important to realize that some Thermologists not current in training claim when patterns become “stable”, it is a normal thermal variant. In some instances, the delta T values of patients with cancer do not increase, and in some cases may decrease. Whenever questionable patterns are seen, they should be monitored semi-annually until the thermologist is convinced the condition is non-pathological.

Implants and Large Breast Size

Patients with large breast tissue size and large implants can decrease the accuracy of thermal screening as the thermographic image becomes cold and the risk of false-negative findings becomes greater. The heat from deeper lying pathologies does not conduct well enough to be seen as a concern for these women. Lower delta T measurements in these patients should be considered suspicious.

Follow-Up Recommendations

The most important job of the thermologist is to assign proper follow-up intervals. Normal breast studies are evaluated and compared to previous baseline studies annually. Studies with mild questionable patterns should be rechecked in six months with more suspicious cases checked in three months. If IBC is suspected, one month is advised. Women with higher risk factors can be screened every six months including those with extensive fibrocystic findings.

Women under Age 50

Recent guidelines in mammography are being challenged for efficacy and safety. Researchers note in the NEJM (7) that over diagnosis is seen in almost 50% of women overall. Other organizations state that mammograms should be reserved for women over 50. This leaves a large percentage of the cancer population to fend for themselves without access to any method of breast screening. 40,000 women under the age of 40 will die from breast cancer each year. This demographic should not be overlooked.

Combining Technologies

Combining the use of modalities generates better outcome measurements. We have been working to incorporate sonography with thermography for screening. These tests are both free of radiation and the initial results prove to be very promising.

Keyserlingk (11) and associates published a retrospective study reviewing the relative ability of clinical examinations, mammography, and infrared imaging to detect 100 new cases of ductal carcinoma in situ, stage I and 2 breast cancers. Results from the study found that the sensitivity for clinical examination alone was 61%, mammography alone was 66%, and infrared imaging alone was 83%. When suspicious and equivocal mammograms were combined, the sensitivity increased to 85%. A sensitivity of 95% was achieved when suspicious and equivocal mammograms were combined with abnormal infrared images. However, when clinical examination, mammography, and infrared images were combined, a sensitivity of 98% was reached.

The potential of lowering the rate of false positives on biopsy is favorable with thermal imaging. All Bi-Rad 3 and 4 mammograms should be thermally screened prior to the decision for biopsy. If Bi-Rad 3 findings were hyperthermic, the need for biopsy would be indicated. If a Bi-Rad 4 were not hyperthermic in the area of significance, then this would not indicate the need for biopsy at that time. This approach has been tested on small samplings of women and requires a larger study design.

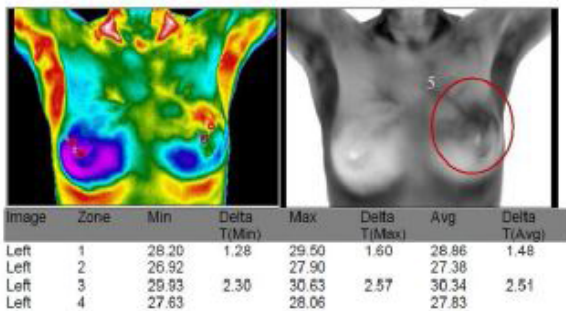
Conclusions

The immediate implementation of thermography into the arena of breast cancer screening is obvious. Evidence based research shows it is drastically needed to reduce the mortality rate of breast cancer as well as false positive rates and thus the over-diagnosis found with mammography.

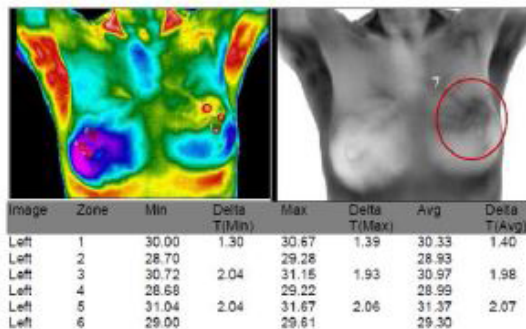
This combination of technologies would have an enormous reduction on the expense on healthcare in the area of biopsy and unnecessary surgeries. Previous biases to this method with older technologies need to be abandoned and physicians should become more familiar with this non-destructive form of testing to better serve their patients.

References:

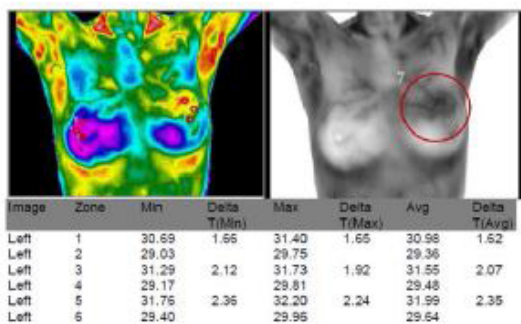
1. Can Med Assoc J > v.75 (4); Aug 15, 1956
2. Gotzsche, P.C. & Olsen, O. Is screening for breast cancer with mammography justifiable?. *The Lancet* 355, 129 - 134 (2000).
3. The Biomedical Engineering Handbook, 3rd Edition, Medical Devices and Systems
4. Hobbins, Wm, Abplanalp. K., Barnes, C., Moner, B.: Analysis of Thermal Class TH-V Examinations in 37,050 Breast Thermograms, Thermal Assessment of Breast Health MTP Press Limited, 25: 249-255, 1984
5. Effectiveness of a noninvasive digital infrared thermal imaging system in the detection of breast cancer, *The Am. J of Surgery*, (2008) 196, 523-526
6. Bryn Mawr Study, No Touch Breast System
7. NEJM, 2012, 367:1998-2005; Nov 2012; Archie Bleyer, MD and Gilbert Welch, MD,
8. Prihodchnko V.V. at al., Modern aspects of prevention for healthy life style - Works of Doneck Clinic N2 "Energetics", 2011.
9. Levshin V.P., Fedichkina T.P. et al. - *Mammology*, 1999, N4, pp. 25-31.
10. Shusharin, A.G., Morozov, V.V. at al. - *Medical Thermography - a Modern Approach - Modern Problems of Science and Education*, 2011, N4.
11. Keyserlignk, J.R., Ahlgren, P.D., et al., Infrared imaging of the breast; initial reappraisal using high-resolution digital technology in 100 successive cases of stage 1 and 2 breast cancer. *Breast J.*, 4,1998.



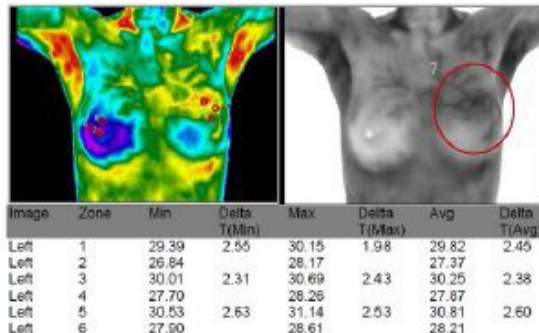
3/19/2012-mk



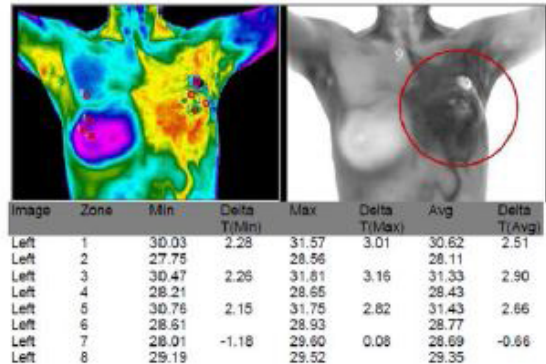
8/2/2012-mk



11/17/2012-mk



2/18/2013-mk

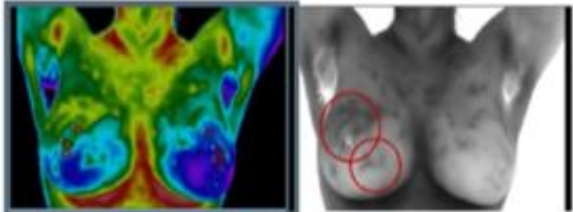


1/14/2014-mk

Patient Passed in 5/2014

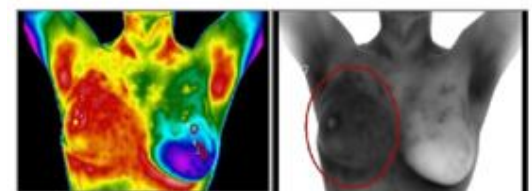
Case MK-1

Fig. MK-1 Patient had a lumpectomy in 2009. The cancer returned and was seen on thermal imaging in March or 2012. The first annual re-exams were relatively unchanged. The fast progression was seen in January 2014.



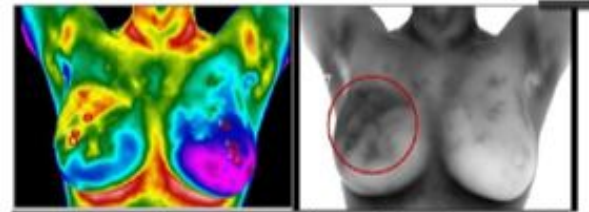
Feb 2012

Image	Zone	Min	Delta T(Min)	Max	Delta T(Max)	Avg	Delta T(Avg)
Left	1	29.85	0.88	30.63	1.11	30.22	1.01
Left	2	28.97		29.52		29.21	
Left	3	30.44	1.12	31.39	1.47	31.01	1.52
Left	4	29.32		29.92		29.49	
Left	5	31.12	1.59	31.91	2.11	31.51	1.84
Left	6	29.53		29.80		29.67	



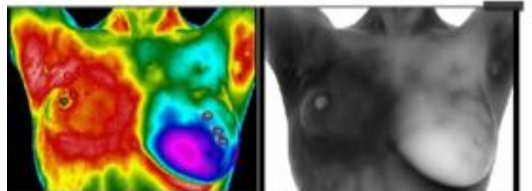
July 2012

Image	Zone	Min	Delta T(Min)	Max	Delta T(Max)	Avg	Delta T(Avg)
Left	1	31.03	2.93	32.32	3.40	31.64	3.26
Left	2	28.10		28.92		28.38	
Left	3	31.58	3.23	33.03	4.00	32.47	3.75
Left	4	28.35		29.03		28.72	
Left	5	32.00	2.88	32.34	2.75	32.15	2.88
Left	6	29.12		29.99		29.27	



May 2012

Image	Zone	Min	Delta T(Min)	Max	Delta T(Max)	Avg	Delta T(Avg)
Left	1	30.52	2.58	31.53	3.09	31.06	2.87
Left	2	27.94		28.44		28.18	
Left	3	30.89	2.53	31.67	3.00	31.23	2.71
Left	4	28.36		28.67		28.52	
Left	5	31.03	2.37	31.53	2.65	31.32	2.57
Left	6	28.66		28.88		28.75	



Sept 2012

Image	Zone	Min	Delta T(Min)	Max	Delta T(Max)	Avg	Delta T(Avg)
Left	1	30.63	1.13	32.24	2.11	31.20	1.42
Left	2	29.50		30.13		29.78	
Left	3	31.17	1.70	32.70	2.76	32.35	2.62
Left	4	29.47		29.94		29.73	
Left	5	32.52	2.86	33.03	2.88	32.79	2.91
Left	6	29.66		30.15		29.88	

Fig. IBC- This image shows the progression of a patient with early thermal signs of Inflammatory Breast Cancer in Feb and a progression until September. The patient passed away in January 2013.